

# Using Internal Jugular Pulsations as a Manometer for Right Atrial Pressure Measurements

Jules Constant

State University of New York at Buffalo, N.Y., USA

## Key Words

Jugular vein · Venous pressure · Hepatojugular reflux · Venous valves · Jugulars, internal · Kussmaul sign · Tricuspid regurgitation · Pericarditis, constrictive · Superior vena cava obstruction

## Abstract

External jugulars are not reliable as an indication of right atrial pressure because of their passage through two right angles and also because they are often not visible. The top level of internal jugular pulsations which are transmitted to the skin of the neck serves as a pulsation manometer. A standard chest angle of 45° and a standard zero at the sternal angle can be used together with a centimeter ruler to give a useful measurement of jugular venous pressure. The use of a carpenter level (spirit level) and a round-bottomed tongue blade measured off in centimeters will allow accurate follow-up. An increase in tone-volume can be detected by the abdominal compression test or abdominojugular test (also known by the outdated terminology of hepatojugular reflux).

Copyright © 2000 S. Karger AG, Basel

## Relation between Jugular and Right Atrial Pressure

In systole the jugular veins are in continuity only with the right atrium because the tricuspid valve is closed. In diastole with the tricuspid valve open, the jugulars are in continuity with both the atrium and right ventricle. Therefore, in diastole jugular pressure measures also right ventricular diastolic pressure.

## Jugular Venous Valves

Valves between the superior vena cava and internal jugulars have been demonstrated when intrathoracic pressure is raised as in coughing or during chest compression for cardiopulmonary resuscitation. The valves usually become incompetent in the presence of tricuspid regurgitation. Doppler studies show that there is no retrograde flow even in the presence of high venous pressure unless there is tricuspid regurgitation [1].

The venous valves do not interfere with the use of jugulars as a manometer for the measurement of right atrial pressure because elevated venous pressures can be transmitted through the venous valves which must remain open during systole as well as during diastole. This is because during systole the descent of the base (floor of the

atrium) lowers right atrial pressure precipitously forcing copious flow from the superior vena cava to the right atrium even though the tricuspid valve is closed.

Any vein in the body may transmit the systolic V waves of severe tricuspid regurgitation, especially apparent in the varicose veins of the leg.

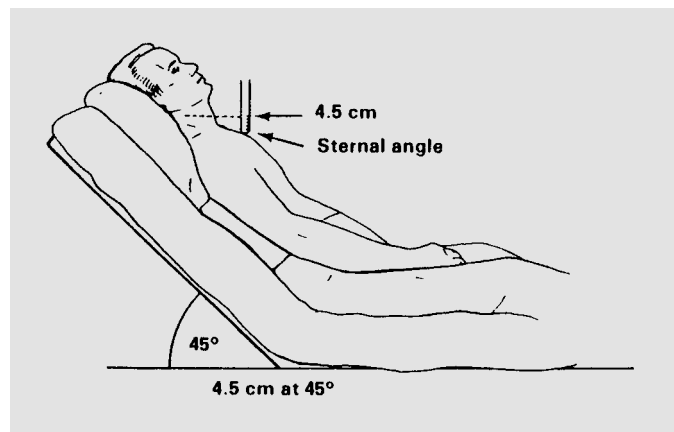
### External versus Internal Jugulars as a Manometer

The internal jugulars are in a direct line with the superior vena cava and right atrium. Therefore, it is in an ideal shape and position to serve as a manometer for right atrial pressure. The external jugulars, on the other hand, are not ideally made for measuring right atrial pressure for three obvious reasons: (1) The external jugular connects with the superior vena cava only after negotiating two angles, i.e., from the superior vena cava to the subclavian and from the subclavian to the external jugular, and each is almost at a 90° angle. The veins are compressed at the point of angulation [2]. (2) The external jugulars are occasionally absent or too thready to be visible to the naked eye, especially in obese females. (3) Although the external jugular may be narrow but still visible when the pressure is normal, in the presence of congestive heart failure (CHF) catecholamines may be elevated to such high levels that the norepinephrine-induced constriction can cause narrow external jugulars to disappear completely [3].

Unfortunately, the internal jugular veins are not visible except with moderate to severe tricuspid regurgitation. Therefore, it seems paradoxical to tell physicians to use internal jugulars for measurement of venous pressure when they are invisible. External jugulars usually can easily be seen as distended, dilated, or engorged when the venous pressure is elevated. Fortunately, the internal jugulars pulsate because they reflect changes in right ventricular volume. These pulsations are transmitted to the skin. The top level of the jugular pulsations may be taken as the right atrial pressure. Thus the internal jugulars may be used as a 'pulsation manometer'.

### The Standard Chest Angle for Jugular Venous Pressure Measurement

Venous pressure is controlled by the volume in the veins and by the tone in the wall of the veins. An elevated venous pressure in CHF is the result of an increase in blood volume caused by the fluid retention and the



**Fig. 1.** Venous pressure can be estimated by observing the upper level of internal jugular pulsations above the sternal angle. If it is over 4.5 cm at 45°, it indicates an elevated right atrial pressure.

increase in venous tone caused by the increase in norepinephrine and sympathetic stimulation.

The venous pressure is different in the supine and sitting positions. At first it seems obvious that the pressure would be higher supine because of the greater increase in volume returning to the heart. However, the vertical position calls for the antigravity mechanism of increased sympathetic stimulation. An increase in sympathetic activity in the upright jugulars seems to overcompensate for the decrease in their volume so that jugular venous pressure may actually be higher sitting than supine. This is one of the reasons for the need of a standard chest angle. A 45° chest angle is a suitable compromise because it is high enough to keep the top level of pulsations below face level where skin pulsations would be lost and yet avoids sitting the patient vertically in which position no one has yet established upper normal values.

### Standard Zero for the Jugular Manometer

The center of the right atrium may be zero for the jugular movements but, unfortunately, it is impossible to know the exact site with the patient at 45°. Therefore, it is obvious that we must use a surrogate for the right atrial center. The most popular one was promulgated by Paul Wood and is the sternal angle, or angle of Louis (pronounced Looie). Fortunately, the upper limit of normal is 4.5 cm, because it is easy to remember 4.5 at 45, i.e., 4.5 cm above the sternal angle with the chest at 45° (fig. 1) [4].

## Obtaining an Accurate Venous Pressure

The top level of pulsations reflects venous pressure with sufficient accuracy to be clinically useful. If the venous pressure is so high that the top level of pulsations cannot be seen at 45°, sitting the patient up with the legs dangling may help. Also, look for earlobe pulsations.

## Jugular Venous Pressure in Tricuspid Regurgitation

It is easy to have the mistaken belief that jugular pulsations are easier to see if the patient is in heart failure. However, because they depend on right atrial and ventricular contraction, if the patient is in heart failure with a low ejection fraction, the pulsations may be difficult to perceive. It should not be surprising to find that if the patient has a high venous pressure and the pulsations are easily visible, you are not seeing a pure venous pressure but one that has been modified by tricuspid regurgitation.

The mean venous pressure in tricuspid regurgitation cannot be read from the internal jugular pulsations because the systolic pressure in the right ventricle is being transmitted directly to the superior vena cava. This may be the only time when it is more accurate to gauge venous pressure from the external jugulars because they do not transmit the right ventricular pressures as readily as do the internals. When the internal jugulars show large pulsations with a very high jugular venous pressure and the external jugulars lower pressure, the latter is probably closer to the true venous pressure.

## Measurement Techniques

Determining the top level of venous pressure really means looking for the fulcrum of internal jugular movements. To make the jugular pulsations easier to perceive, it is useful to shine a light tangentially from behind or in front of the neck to throw a jugular shadow. Then examine the silhouette of the neck. When you are examining the right side of the neck, you should lean over to the left side of the patient to obtain a view of the silhouette of the skin overlying the right internal jugular. Next, you should look for earlobe pulsations.

Jugular pulsations should be looked for mainly during inspiration, because with inspiration the increased blood volume to the right ventricle causes an increase in right ventricular ejection with the resultant larger jugular am-

plitude. Also, since the superior vena cava is an intrathoracic organ, it responds to intrathoracic changes, and if bronchospasm is present, expiration can raise intrathoracic pressure to give a false impression of elevated jugular venous pressure. Any more than a slight rise in venous pressure on expiration gives added information, i.e. it suggests the presence of bronchospasm.

The most accurate venous pressure is seen when the right rather than the left jugular is examined. This is partly because more blood comes from the right side of the head than the left, thus making movements of the right jugulars easier to see. Also, in some elderly subjects with tortuous aortas the innominate vein can be compressed against the sternum by the aortic arch and can falsely raise the left jugular pressure. Finally, in some patients the left superior vena cava drains into the coronary sinus, thus creating some obstruction to the emptying of the left jugular. Clinical use can be made of this fact, especially in patients with atrial septal defects in whom this anomalous drainage is most likely. Since the right jugular is normally either at the same level or higher than the left because of the increased flow to the right, if the reverse is true, then an anomalous drainage of the left superior vena cava should be considered.

To get an accurate measurement it is convenient to mark off centimeters on a tongue blade (tongue depressor) and place the rounded bottom on the sternal angle. This is more comfortable than a ruler which usually has sharp edges. Then by means of a carpenter's level (spirit level) measure the horizontal level at the site of the uppermost skin movements of the internal jugular pulsations. Now you can follow the course of the venous pressure accurately in centimeters from day to day. In the absence of a ruler of any kind, fingers can be used by placing them on the sternal angle and getting a rough estimate by noting that each finger at the proximal interphalangeal joint is about 2 cm in diameter. A closed fist on the sternal angle serves this purpose well [5].

## The Abdominal Compression Test or Hepatojugular Reflux

If the venous pressure is below 4.5 cm, let us say 3 cm, it may be below a maximum normal level but it may not be normal for that individual because the upper normal level for that person may be 1 cm and may have risen 2 cm because of CHF, i.e. the patient had an increase in venous tone or volume but it was not detected. Increased venous tone has been found in all patients with so-called right

ventricular failure, i.e. peripheral venous congestion (increased venous pressure and peripheral edema) [6]. If diuretics have normalized the absolute height of venous pressure, abdominal compression may still demonstrate the increased tone. The increased tone and volume due to a fall in cardiac output may be called an increase in 'tone-volume'. A tone-volume increase can be produced by left ventricular dysfunction with an increase in left atrial pressure of 15 mm Hg or more, or by pure right ventricular dysfunction (as in right ventricular infarction) with a normal wedge pressure [7]. The abdominal compression test is a test for an increase in tone-volume irrespective of the cause.

The term positive abdominal compression test is preferable when describing the results of abdominal pressure. The term 'abdominal jugular test' has also been proposed but for teaching purposes the word 'compression' is more specific [8].

Abdominal compression causes and maintains a rise of at least 1 cm in the top level of pulsations only if there is an increase in tone-volume. The greater the rise produced by abdominal compression, the greater is the increase in tone-volume.

The test, commonly called the hepatojugular reflux (not reflex), is a useful term only for purposes of indexing. It is an historical term. In 1885 William Pasteur (a British physician) applied pressure over a large congested liver in a patient with severe tricuspid regurgitation and noted an increase in jugular venous distention. He described it as simply a test for tricuspid regurgitation [9]. Rondot [10] considered that a positive response indicated weakness of the right ventricle. He named it the 'hepatojugular reflux'. Later studies showed that the effect can be achieved even with a normal-sized liver and with compression on any part of the abdomen, although right upper quadrant pressure produced the greatest response [11, 12].

If pressure on the liver is not the cause of the increased tone-volume, we must look for another cause. A second mechanism for the increased jugular venous pressure with abdominal compression is that blood is displaced from the abdominal viscera by the compression. Pressure on the abdomen transmitted to a venous system with normal tone or distensibility would squeeze blood out of the splanchnic area and force it into veins which would accommodate the added amount by an increase in the volume without changing their tone. With CHF the venous system is adjusted for high tone and forcing blood into veins with high tone from the splanchnic area will raise the venous pressure in the recipient veins [13]. It is a well-known engineering principle that if tension is raised

equally in vessels of all sizes the blood would be forced from the smaller ones into the larger ones which, in this case, would be the vena cava.

A third mechanism for raising venous pressure with abdominal compression is the finding that pressure on the abdomen can reflexly raise pressure in an isolated venous segment, and that the infiltration of procaine into the segment could abolish the reflex in pressure. Thus abdominal compression by itself probably increases venous tone and thus contributes to the rise in venous pressure [14]. A fourth mechanism is the probability that the effect is at least partly due to pressure on the right atrium or right ventricle which also have an increase in tone-volume. It is possible that upward pressure of the diaphragm against the right atrium and right ventricle which have decreased compliance as well as increased volume may then resist receiving blood from the superior vena cava.

There are many noncardiac causes of rises in venous pressure with abdominal compression, e.g. (1) patients with severe loss of vital capacity may not be able to tolerate the upward movement of the diaphragm due to pressure on the abdomen, (2) an increased sympathetic stimulation due to such causes as nervousness, pain, or an acute infarction, and (3) an increased blood volume of any etiology.

### **How to Avoid False-Positive Elevations in Venous Pressure due to Sympathetic Stimulation**

- 1 Compress with warm hands or with a garment or sheet between your hand and the abdomen.
- 2 Spread the fingers apart so that there is as little local pressure as possible.
- 3 Start by pressing gently, gradually increasing the pressure to just below the point of discomfort.
- 4 Warn the patient that it spoils the test if you produce discomfort. This lets the patient know that you are not going to produce any discomfort.

### **Kussmaul Sign**

A rise in jugular venous pressure with inspiration is known as the Kussmaul sign. Although typically it is found in patients with constriction, it is found in a minority of such patients, and it often occurs with peripheral venous congestion from any cause. In constriction more commonly there is no change in jugular venous pressure

while in normal subjects and in tamponade, the jugular venous pressure falls with inspiration [15].

The Kussmaul sign can also occur with pulmonary embolism and right ventricular infarction [16]. This sign should also alert you to the presence of right ventricular infarction in a patient with acute inferior infarction even with no sign of left ventricular failure [17].

### **As a Test for the Site of Superior Vena cava Obstruction**

The azygos vein joins the inferior vena cava to the superior vena cava. If the obstruction is between the azygos and its entrance into the right atrium, abdominal compression forces more blood proximal to the obstruction and the jugular venous pressure will rise.

### **Significance of Neck Vein Descriptions**

It is common to read descriptions of jugular veins as being distended or engorged, or conversely 'flat'. Since internal jugulars are too deep to be visible, those descriptions are almost certainly of the external jugulars. It implies that the physician is not analyzing internal jugulars. I have seen patients with very high venous pressures in whom the jugular pressures were reported to be normal by both residents and cardiology consultants because they noted that the 'neck veins were flat'. It was apparent that they were not trained to examine internal jugular pulsations. In one such patient the internal jugular pressure was so high that the earlobes were pulsating! Only by stressing the importance of estimating the venous pressure by utilizing the internal jugular pulsation manometer can the use of invasive monitoring for venous pressure be avoided.

### **References**

- 1 Sivaciyan V, Ranganathan N: Transcutaneous Doppler jugular venous flow velocity recording. *Circulation* 1978;57:930-939.
- 2 Guyton AC: The venous system and its role in the circulation. *Mod Concepts Cardiovasc Dis* 1958;27:483-487.
- 3 Sharpey-Schafer EP, Ginsburg J: Humoral agents and venous tone. *Lancet* 1962;ii:1337.
- 4 Constant J: *Bedside Cardiology*, ed 5. New York, Lippincott, Williams & Wilkins, 1999;p 69.
- 5 Constant J: *Bedside Cardiology*, ed 5. New York, Lippincott, Williams & Wilkins, 1999;p 72.
- 6 Sharpey-Schafer EP: Venous tone. *Br Med J* 1961;2:1589.
- 7 Ewy GA: The abdominojugular test. *Ann Intern Med* 1986;109:456.
- 8 Ewy GA: The abdominojugular test: Technique and hemodynamic correlates. *Ann Intern Med* 1988;109:456-460.
- 9 Pasteur W: Note on a new physical sign of tricuspid regurgitation. *Lancet* 1985;ii:524.
- 10 Rondot E: Le reflux hépato-jugulaire. *Gaz Hebd Sci Med Bordeaux*, 1898;19:567.
- 11 Hultgren HN: The effect of increased venous return on venous pressure. *Am Heart J* 1950; 39:592.
- 12 Moia B: *Cardiology Methods*. New York, McGraw-Hill, 1959;vol 2;p 38.
- 13 Burch GE: The effects of hexamethonium on venous pressure in congestive heart failure. *Circulation* 1955;11:271.
- 14 Burch GE, Murtadha M: A study of venomotor tone in a short intact venous segment of the forearm. *Am Heart J* 1956;51:807.
- 15 Constant J, Lippschutz EJ: The one-minute abdominal compression test or 'the hepatojugular reflux', a useful bedside test. *Am Heart J* 1965;67:701-707.
- 16 Shabetai R: *The Pericardium*. New York, Grune & Stratton 1981;p 243.
- 17 Butman S, Olson H, Aronow WS, Lyons KP: Remote right ventricular myocardial infarction mimicking chronic pericardial constriction. *Am Heart J* 1982;103:912-914.